
Renal/Hepatotoxicity of Bonny Light Crude Oil Use for Folkloric Medicine.

T. Odinga and G.G. Ngelale

Rivers state university of science and technology,
Port Harcourt, Nigeria
Bomaodinga@gmail.com

Abstract

The use of Bonny Light Crude Oil in the southern part of Nigeria for folkloric medicine and its renal/hepatic toxicity was investigated in wistar albino rats. Physicochemical analysis was carried out on the Bonny Light Crude Oil sample to ascertain its components. Fifteen rats of average weight 120g were used. The rats were grouped into 5 groups of 3 rats each and administered with 0.5, 1.0, 1.5 and 2.0mls per kg body weight respectively with group 1 as the control group. The Bonny Light Crude Oil was administered 24-hourly for 7days using the intragastric via gavage mode of administration. The effect of the bonny light crude oil on the integrity of the renal and hepatic cells was assessed. The levels of the hepatic biomarker enzymes: Alanine Transferase, Aspartate Transaminase, Alkaline Phosphatase were significantly increased at the $P \leq 0.05$ level compared to the control. The renal biomarkers Creatinine and Blood urea levels also had a significant increase at the $P \leq 0.05$ level compared to the control. Histopathological examination indicates that Bonny Light Crude Oil had a considerable distortion on the integrity of the renal and hepatic cell of the Wistar Albino Rat.

Keywords: folkloric medicine, crude oil, physicochemical, renal toxicity, hepatotoxicity.

INTRODUCTION

Crude Oil has been described as a complex mixture of over 6000 potentially different hydrocarbons and metals (Edward, 2003). It has the potential to elicit multiple types of toxic effects such as acute lethal toxicity, sub-lethal chronic toxicity or both depending on the exposure, dosage and the organism exposed. Some Polycyclic Aromatic Hydrocarbon components of petroleum have the potential to bio-accumulate within susceptible aquatic organisms and by pass by tropic transfer to other levels of the food chain (Eisler, 1987). Hence exposure to crude oil through oil spillage, and activities of the petroleum industries and vandalization can cause very serious environmental pollution.

Crude oil is taken orally in many oil producing communities of Nigeria for the “laxative effect” or a general antidote “against poisonous substances” and witchcraft.(Orisakwe et al.,2004, Udoele, 1997).

Arikpo et al., 2009 observed 69% of the populace of four local governments in Akwaibom and Cross rivers state of southern Nigeria use crude oil and other petroleum distillates in treatment of ailments. Lack of adequate health institutes, personnel, and facilities to provide quality care lends itself to the reliance of crude oil for treatment of ailments.

Dede et al, 2002 reported cases of misuse of crude oil by individuals as it is known to be used liberally by some of the indigenes who believe that it can repel witches when applied by oral

administration or topically on afflicted individuals. Also it is used for unorthodox treatment of ailments such as stomach aches, diarrhea, respiratory distress and convulsion. Hence this study evaluates the hepatic and renal toxicity of oral intake of crude oil in wistar albino rats.

MATERIAL AND METHOD

Fifteen Albino rat with average body weight of 120g were used. The animals were kept in ventilated metal cages and feed with commercial rat chow and supply of water *ad libitum*. Animals were grouped into 5 of 3rats in each group. Group 1 as control and Bonny Light Crude Oil (BLCO) administered to the other four groups using the intragastric via gavage method in the doses below:

Group 1	control (Normal feed and Water)
Group 2	0.5ml/kgbw of BLCO
Group 3	1.0ml/kgbw of BLCO
Group 4	1.5ml/kgbw of BLCO
Group 5	2.0ml/kgbw of BLCO

The wistar albino rats were sacrificed on day 7 of the experiment. Blood samples were collected by cardiac puncture and put in lithium heparin bottle to determine the integrity of the hepatic and renal cells using enzyme biomarkers for hepatic and renal functions. The enzyme assay method as guided by the Randox enzyme kit laboratories, United Kingdom was used. The liver and kidney were excised and put into sample bottles containing formalin for histological examination.

All physicochemical analysis was carried out in line with the ASTM.

RESULTS

Table 1 : Physicochemical Analysis of test sample

Parameters	Sample result	Test Method (Sample)	ASTM	Units	Chevron Standard
Temperature	29.0	ASTMD 3230	-	°C	-
Viscosity	3.45	ASTM 0446	-		1220
Specific gravity	0.873		0.8498 Max		0.85
American Petroleum institute gravity	32.8		37.9 max		35.30
Salt content	0.48	ASTM D2547	47	%	-
Acid number	0.21	ASTM D2547	0.39 max	mgKoHg	0.23
Sulphur	0.04	ASTM D54-53	0.14	%W	0.15
Nitrates	0.83	ASTM D4046	-	Mg/l	1084.85
Water content	0.07	ASTM D4007	1.00 max	%	-
Vanadium	0.42	ASTM D5863	2.00max	Ppm	0.44
Nickel	3.87	ASTM D5863	4.00 max	Ppm	4.13

Table2: Effect of BLCO on the hepatic function

	AST (u/l)	ALT (u/l)	ALP (u/l)
Control	24.33±2.309 ^a	12.00±0.000 ^a	38.00±11.53 ^a
Group 2	30.00± 5.196 ^b	13.67±2.887 ^b	43.67±6.807 ^b
Group 3	43.33± 7.62 ^c	16.67±4.509 ^c	45.67±6.429 ^c
Group 4	59.33±7.506 ^d	19.33±8.737 ^d	46.00±3.000 ^c
Group 5	60.67±14.57 ^e	23.67±2.309 ^e	46.00±13.00 ^c

- Values are mean ± standard Deviation
- Statistical analysis was done using one way ANOVA.
- Values in the same column with different superscript are significantly different at (P< 0.05).
- Values in the same column with the same superscript are not significantly different at (P>0.05)

Table 3: Effect of Bonny light crude oil on the Renal Function

	UR (mmol/l)	CR (umol/)
Control	2.700±0.173 ^a	198.0±5.568 ^a
Group 2	3.000±0.173 ^b	199.0±6.245 ^b
Group 3	3.233±0.568 ^c	204.7±4.726 ^c
Group 4	4.167±1.379 ^d	204.3±112.50 ^d
Group 5	4.500±0.173 ^e	213.7±14.50 ^e

- Values are mean ± standard Deviation
- Statistical analysis was don using one way ANOVA
- Value in the same column with different superscript are significantly different at (P<0.05)

Photomicrographs of the hepatic cells

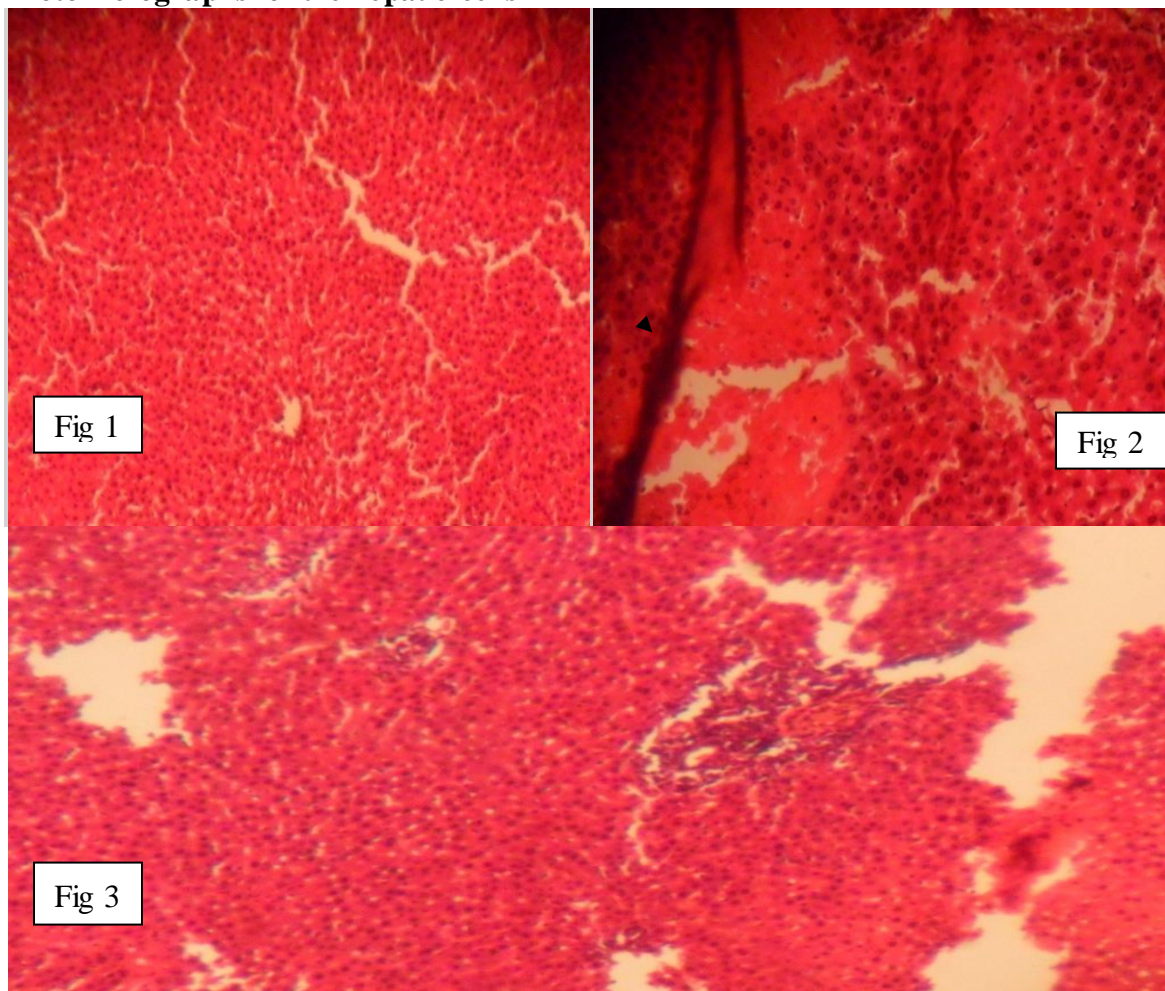


Fig 1: photomicrograph of the control liver showing normal histology.

Fig 2: photomicrograph of hepatic cell showing inflammatory cells, hepatocyte degeneration and hemorrhage.

Fig 3: photomicrograph of hepatic cell showing architectural distortion.

Photomicrographs of the renal cells

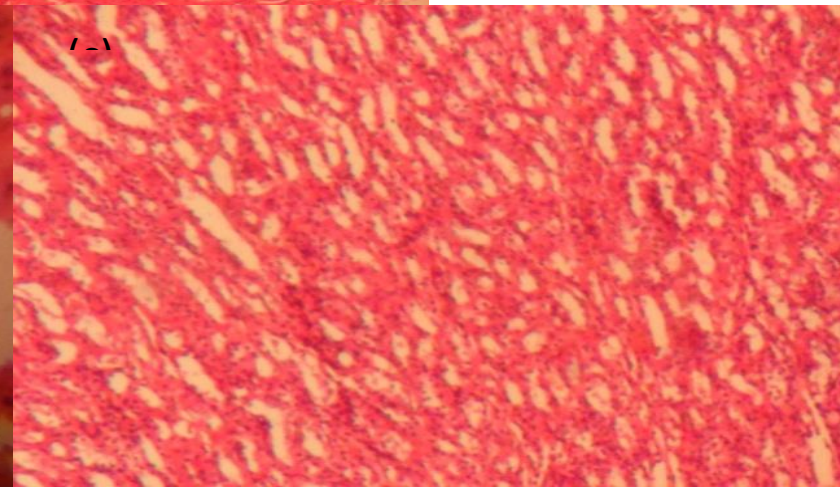
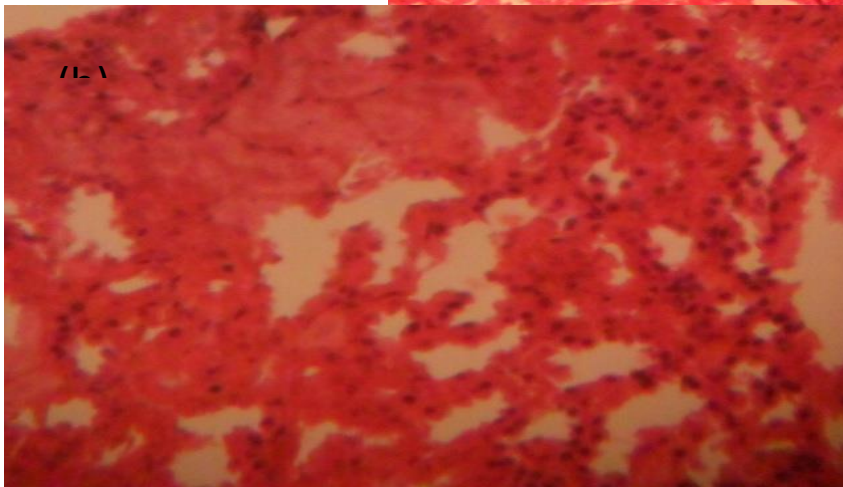
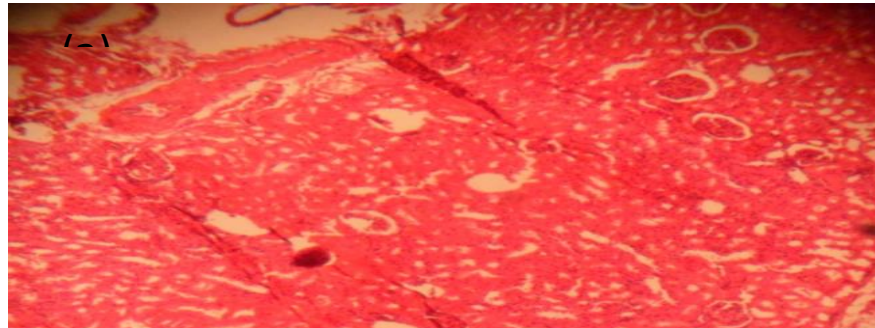


Fig 1: photomicrograph of the control kidney showing normal histology

Fig 2: photomicrograph of renal cell showing inflammation, degenerative changes.

Fig 3: photomicrograph of renal cell showing architectural distortion.

Fig 2

DISCUSSION

The physicochemical analysis result revealed the components of the bonny light crude oil in their acceptable proportion. The biomarker enzymes determined for the hepatic function in the wistar albino rat are Aspartate Aminotransferase (AST), Alanine Aminotransferase (ALT) and alkaline phosphatase (ALP). The result of this study showed a significant increase in the levels of the hepatic biomarker enzymes in the rats exposed to oral intake of bonny light crude oil. The increase is seen to be proportional to the dosage compared to the control. The significant increase in these enzymes biomarkers indicates a considerable damage on the hepatic function of the experimental animals, which can lead to dysfunction of the hepatic cell, giving rise to diseases such as Odema. (Otitoju et al., 2007) showed that bioaccumulation of crude oil residues in the endocrine system over a long period of time may lead a lot of health problems such as dysfunction of the hormonal system which can consequently affect the reproductive system.

Creatinine and Blood Urea Level are indicators of overall renal function. The result of creatinine and urea levels in the blood showed $P \leq 0.05$ significant level when compared to the control. The significant increase in the renal biomarkers when compared to the control highlights considerable damage in the renal function of the experimental animals. This damage was suspected to be as a result of the hydrocarbon content of BLCO and also its metal content. (Odinga et al., 2015) observed that the presence of Polycyclic aromatic hydrocarbon in the body leads to various disease conditions such as acute renal failure, hepatic and reproductive dysfunction.

The histopathology examination photomicrographs revealed various damages of the renal and hepatic cells.

This research hence reveal that the exposure of humans to Bonny light crude oil orally for folkloric medicine has the potential to alter the integrity of the hepatic and renal cells, its use therefore should be totally brought to a halt .

List of abbreviation

BLCO-	Bonny light crude oil
AST-	Aspartate Aminotransferase
ALT-	Alanine Aminotransferase
ALP-	Alkaline phosphatase
PAH-	Polycyclic aromatic hydrocarbon
ANOVA-	Analysis of Variance
ASTM-	American society of the international association for testing and materials

References

- Adesanya OA, Shittu LA, Omonigbehin EA, Tayo AO.(2009). Spermatotoxic impact of bonny light crude oil (BLCO) ingestion on adult male Swiss albino mice. *Int J Physical Sci*;4(5):349-353. Available: <http://www.academicjournals.org/IJPS>.
- Afonne OJ, Onyiaorah IV, Orisakwe OE.(2013). Toxicity of Chevron Escravos crude oil and chemical dispersant on guinea pig testicular function. *J Basic Clin Physiol Pharmacol*;0:1-9. DOI: 10.1515/jbcpp-2012-0060.
- Dede EB, Igboh NM, Ayalogu OA. (2002)Chronic study of crude petroleum bonny light, kerosene, and gasoline using haematological parameters. *J Appl Sci Environ Management*;6(1):60-66

- Edwards, C.W.(2003) Toxicology of Oil Field Waste Hazards to lives stocks associated with the Petroleum industrial. *vet.din.Amer*.5,363-374.
- Eisler R.(1987) Polycyclic aromatic hydrocarbon hazards to fish, wildlife, and invertebrates: A synoptic review. Fish and Wildlife Service. Washington, DC: U.S. Department of Interior; pp. 85, 1.11
- G. Arikpo, M. Eja, K. Enyi-Idoh.(2009). Self medication in rural Africa : the Nigerian experience. *The internet journal of health*. Vol. 11, number 1.
- Igwebuike UM, Obidike RI, Shoyinka SVO, Nwankwo IO, Okwechime IO, Aka LO.(2007) Effects of Nigerian Qua-iboe Brent Crude oil on rat spleen and haematological parameters. *Vet Arch.*;77:247-256.
- John WB, Jonne AM, Ballache E.(1996). Flow-cytometric determination of genotoxic effects of exposure to petroleum in mink and see offers. *Ach Environ Contamination Toxicol.*;30:349-355.
- Kalf GF, Post GB, Snyder R.(1987) Solvent Toxicology: recent advance in the toxicology of benzene, the xycol ethers and carbondetra chloride. *Annu. Rev. Pharmacol, Toxicol.*;27:399-427
- Ngokere AA, Okoye JO, Ogenyi SI, Bukar SM, Ude T.(2014) Histopathological and biochemical disrupting effects of Escravos crude oil on the liver and heart in Chinchilla rabbits. *Afr. J. Environ. Sci. Technol.*;8(3):203-209. DOI: 10.5897/AJEST2013.1643
- Odinga T.B, Ayalogu E.O,Essien E.B.(2015). Physicochemical and hydrocarbon content of effluent from port Harcourt refining company and its effect on renal function of albino rats.*J.Research in environ . Sci. tech.*;4(2):
- Okoye JO, Ngokere AA, Okeke AC.(2014) Biochemical, haematological and histological effects following Escravos crude oil ingestion by Chinchilla rabbits. *Int J Med Med Sci.*;6(2):63-68. DOI: 10.5897/IJMMS2013.1015
- Orisakwe OE, Njan AA, Akumka DD, Orish VN, Udemezue OO.(2004) *Int. J. Env. Res. and Public Health*;1(2):106–110.
- Otitoju O, Onwurah INE(2007) Preliminary investigation into the possible endocrine disrupting activity of Bonny light crude oil contaminated diet on Wistar rats. *Biokemistri J.*;19(2):23-28.
- Otitoju O, Onwurah INE, Otitoju GTO, Ndem JI, Uwah AF. Effect of Bonny light crude oil contaminated diet on serum cholesterol and testosterone concentrations inwistar albino rats. *Afr J Biotechnol.* 2011;10(53):10986-10990.
- Udoele, U.B., 1997. Toxicological evaluation of qua iboe crude oil in rats. M.Sc thesis , university of calabar, calabar, Nigeria. Pp:178.